May-Thurner Syndrom (MTS)

Stefan Ockert

Hirslanden Klinik St. Anna
LUVAS Gefässchirurgie
Luzern

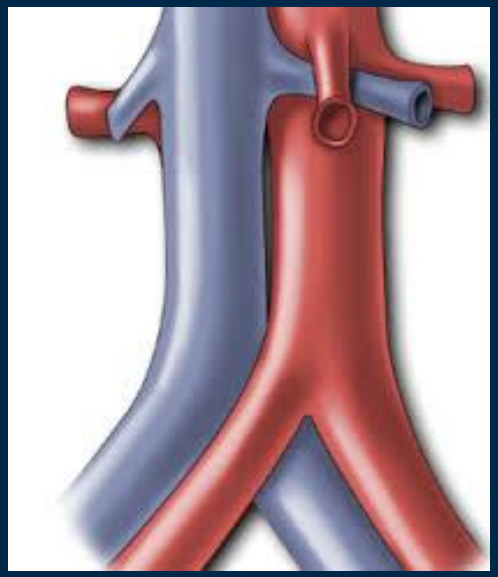

Historie

THE CAUSE OF THE PREDOMINANTLY SINISTRAL OCCURRENCE OF THROMBOSIS OF THE PELVIC VEINS[1]

R. MAY, M.D., AND J. THURNER, M.D.

In 1950 Wanke, Kiel, described a new operative method for the surgical treatment of sequelae after old cases of thrombosis of the pelvic veins. He found that the narrowing of the v. iliaca ext. and communis is frequently caused not so much by the lacking recanalization of the vein but rather by compression *from without* as a result of a cicatricial sclerotic transformation of the common sheath caused by former perivenous inflammation. Wanke mentions a *closure of the pelvic vessels* and therefore recommends shelling out of the callus-like transformations of the sheath. In this we were successful on the occasion of the first operation of this kind performed by us in 1955 (fig. 1). Further surgical opera-

1851	**Virchow**	**Erstbeschreibung IFTVT 5-fach links erhöht**
1908	**Mc Murrich**	**Kadaveruntersuchung mit Stenosen V. iliaca**
1943	**Ehrich**	**Kadaveranalyse Obstruktionen**
1957	**May+Thurner**	**Venensporn bei 430 Kadavern in 22% (Angiology)**
1965	**Cockett**	**asympt. LCIV, aber irreversibel**

Namensgeber MTS



Robert May 1912-1984 Chirurg Innsbruck



Josef Thurner 1927 Pathologe Innsbruck

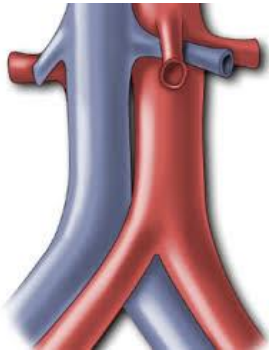

Pathophysiologie

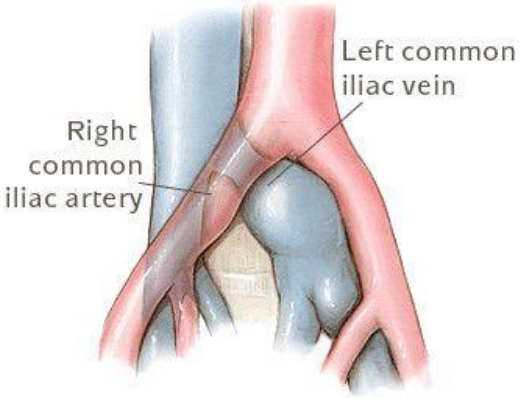

repetitive Mikrotraumen der VIC links
Verklemmung der VIC zwischen AIC rechts und 5 LWK

- **Endothelstress >>> Intimahyperplasie**
- **Fibrinstrang-/Kollagennetz-/Venenspornbildung**
- **konsekutive Flussverlangsamung**

Ausbildung von descendierender TVT (akut/chronsich)

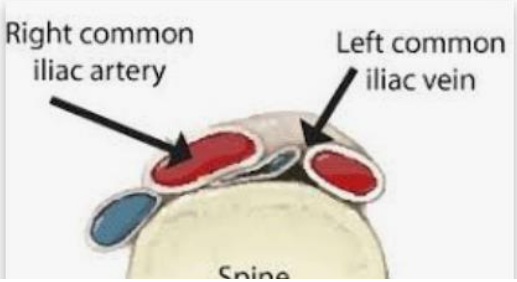

Inzidenz MTS

- 24% asympt. Patienten mit >50% Kompression der VIC links
- anatomische Variante >50% Stenose >>>Ausbildung Endothelschädigung
- Vorkommen bei 2-5% aller Patienten mit venöser Erkrankung
- 18-49% bei IFTVT
- 3-8 mal höher links als rechts

- Frauen> Männer (5:1)
- Häufigkeit 2-3 Lebensdekade

Auslöser TVT bei MTS:

- Immobilisierung
- Operative Eingriffe
- Übergewicht
- Schwangerschaft

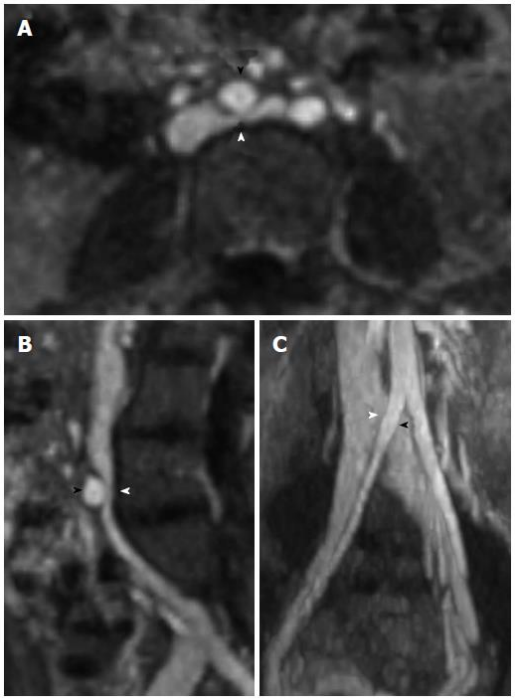

Brinegar KN et al WJR 2015

Klinik und Stadien MTS

Stadium I:	**asymptomatisch, VIC-Kompression**
Stadium II:	**Venensporn**
Stadium III:	**Iliofemoral TVT links**

chronisch. MTS/Differentialdiagnosen

chronisch MTS:

- rezediv. linksseitige TVT
- unklare linksseitige Beinschwellung
- Claudication venosa
- Hyperpigmentierung
- Varikosis

DD:

- Trauma
- Operative Einrgriffe
- Immobilisation
- Kathetereingriffe
- Strahlentherapie
- Maligne Erkrankungen

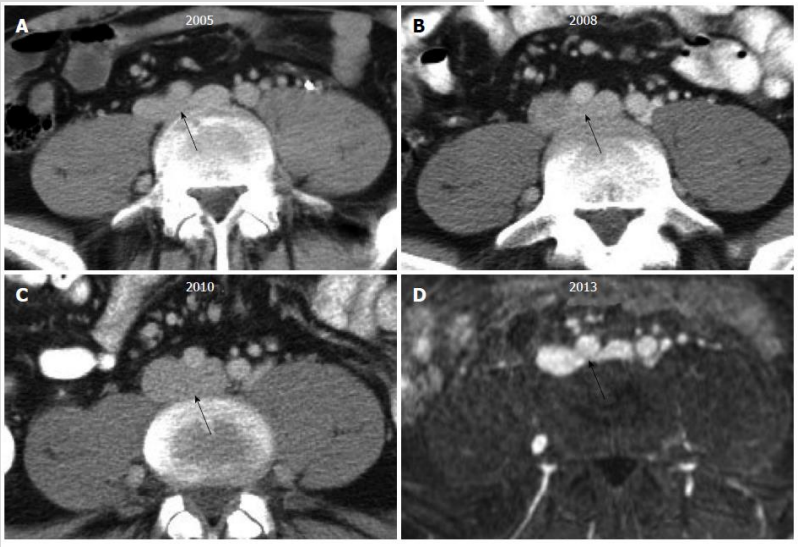

Brinegar KN et al WJR 2015

Kompression und Risiko für TVT

230 Patienten V.a. einseitige TVT mit CT Diagnostik

Ergebnisse:

Mean Kompression 36.6%
29.7% Kompression >50%
7.2% > Kompression> 70%

Fazit:
CT- Kompression: **> 70% erhöhtes Risiko für TVT**
>50% kein erhöhtes Risiko
linksseitige TVT weniger PE als rechts!



Radiology

Iliac Vein Compression as Risk Factor for Left- versus Right-Sided Deep Venous Thrombosis: Case-Control Study[1]

Anand Narayan, MD, PhD
John Eng, MD
Lemore Carmi, MD
Siobhan McGrane, MBBCh
Muneeb Ahmed, MD
A. Richey Sharrett, MD, DrPH
Michael Streiff, MD
Josef Coresh, MD, PhD, MHS
Neil Powe, MD, MPH, MBA
Kelvin Hong, MD

Purpose: To determine if compression of the left common iliac vein (LCIV) by the right common iliac artery is associated with left-sided deep venous thrombosis (DVT).

Materials and Methods: This institutional review board–approved case-control study was performed in a cohort of 230 consecutive patients (94 men, 136 women; mean age, 57.5 years; range, 10–94 years) at one institution who had undergone contrast material–enhanced computed tomography of the pelvis prior to a diagnosis of unilateral DVT. Demographic data and information on risk factors were collected. Two board-certified radiologists determined iliac vein compression by using quantitative measures of percentage compression [{1 minus (LCIV diameter at point of maximal compression/distal right common iliac ven diameter)} times 100%], as well as qualitative measures (none, mild, moderate, severe), with estimates of measurement variability. Logistic regression analysis was performed (independent variable, left vs right DVT; dependent variable, iliac vein compression). Cutpoints of relevant compression were evaluated by using splines. Means (with 95% confidence intervals [CIs]) and odds ratios (ORs) (and 95% CIs) of left DVT per 1% increase in percentage compression were calculated.

Results: Patients with right DVT were more likely than those with left DVT to have a history of pulmonary embolism. Overall, in all study patients, mean percentage compression was 36.6%. 66 (29.7%) of 222 had greater than 50% compression, and 16 (7.2%) had greater than 70% compression. At most levels of compression, increasing compression was not associated with left DVT (adjusted ORs, 1.00, 0.90, 1.02) but above 70%, LCIV compression may be associated with left DVT (adjusted ORs, 3.03, 0.91, 10.15).

Conclusion: Increasing levels of percentage compression were not associated with left-sided DVT up to 70%; however, greater than 70% compression may be associated with left DVT.

[1]From the Johns Hopkins Hospital, Baltimore, Md (A.N., J.E., L.C., S.M., M.S., J.C., K.H.); Johns Hopkins Bloomberg School of Public Health, 2024 E Monument St, Suite 1-5000, Baltimore, MD 21205 (A.N., A.R.S., J.C.); San Francisco General Hospital, San Francisco, Calif (N.P.); and Beth Israel Deaconess Medical Center, Boston, Mass (M.A.).
From the 2010 RSNA Annual Meeting. Received August 10, 2011; revision requested September 22; revision received February 2, 2012; accepted March 2; final version accepted June 5. Address correspondence to A.N.

© RSNA, 2012

Supplemental material: http://radiology.rsna.org/lookup/suppl/doi:10.1148/radiol.12111580/-/DC1

Diagnostik I

Zeichen für MTS

- 40% Flussreduktion links vs. rechts
- turbulenter Fluss/poststeotischer Fluss (Labrodopolous et al)

Indirekte Zeichen einer zentralen Stenose/prox Obstruction bei Duplex VFC:

- **fehlende Flussveränderung** bei Atemmodulation bei offener AFC
- **fehlende Reaktion auf Valsalva** als Hinweis für eine prox. Obsuktion (MTS)

50% suboptimale Bedingungen (Darmgasüberlagerung)
47% Sensitivität Duplex VIC

Diagnostik II

Schnittbildgebung

- CT (V) (Kollateralisation/Auschluss Tumor)
- MRI

Alternativ: (Phlebo/-Venographie)

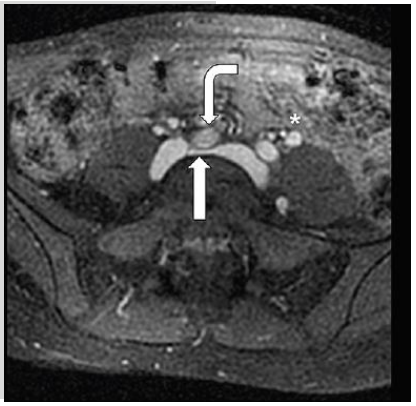

➢ Intravaskulärer Ultraschall (IVUS)

Pros:

- direkter intravaskulärer Nachweis: Venensporn/Web/Intimahyperplasie

Cons:

- invasiv
- kein Nachweis extravaskulärer Ursachen

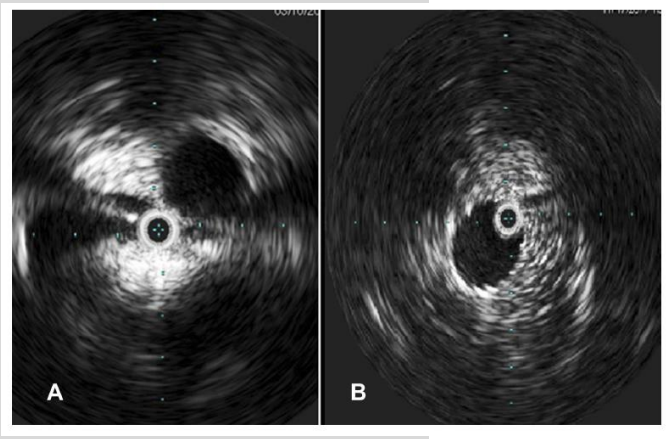

Radaideh 2019 et al; Vasc HRM

Therapie MTS

Berger 1995 **CDT+Stenimplantation**
Claudication Venosa und Schwellung

- **singuläre Angioplastie nicht sinnvoll**
- **ca 1/3 IFDVT mit Kompression und Stenting**
- **48% Stenting in eigener Serie mit IFDVT**

Acute Venous Iliofemoral Thrombosis: Early Surgical Thrombectomy Is Effective and Durable

Stefan Ockert,[1] Matthias von Allmen,[1] Michaela Heidemann,[2] Juliette Brusa,[1] Jan Duwe,[1] and Robert Seelos,[1] Lucerne, Switzerland

Knuttinen et al Cardivasc Diagn Ther 2017

Therapie MTS: Stents

primäre Anwendung Wallstent:

- **schwierige Positionierung**
- **unkalk. Verkürzung**
- **Recoil/Radialkraft**

aktuell Nitinolstents:

- **keine Verkürzung**
- **akkurate Positionierung**
- **Radialkraft**
- **Bruchresistenz**

Stent (manufacturer)	VICI (Boston Scientific)	Zilver Vena (Cook)	Sinus Venous (Optimed)	Venovo (Bard)	ABRE (Medtronic)	Wallstent (Boston Scientific)
Material/ structure/ production	Laser cut, open cell, nitinol	Laser cut, open cell, nitinol	Laser cut, 2 open cell, nitinol	Laser cut, open cell nitinol	Nitinol	Elgiloy
Expansion	Self-expanding	Self-expanding	Self-expanding, balloon expandable at kissing portion	Self-expanding	Self-expanding	Self-expanding
Sheath size/ platform	9F/0.035"	6F/0.035"	10F	8,9,10F/0.035"	9F/0.035"	6–10F/0.035"
Foreshortening	10–15% foreshortening	No foreshortening	No foreshortening	No foreshortening	?	30–40% foreshortening
Radial force	++++	++	+++	++++	?	+
Diameter	Up to 16 mm	Up to 16 mm	Up to18 mm	Up to 20 mm	Up to 20 mm	Up to 24 mm
Length	60–120 mm	60,100,140 mm	60–150 mm	40–160 mm	40–150 mm	20–94 mm
Trial	VIRTUS	VIVO (EU)	Lichtenberg et al[45,41]	VERNACULAR	ABRE	None

Note: ++++, strongest; +++, strong; ++,weak; +, weakest; ?, unknown.[46]
Abbrivation: F, French; mm, Millimeter.

➢ **aktuell keine Vergleichstudie Wallstent vs. Nitinol**

Diagnostik intraoperativ

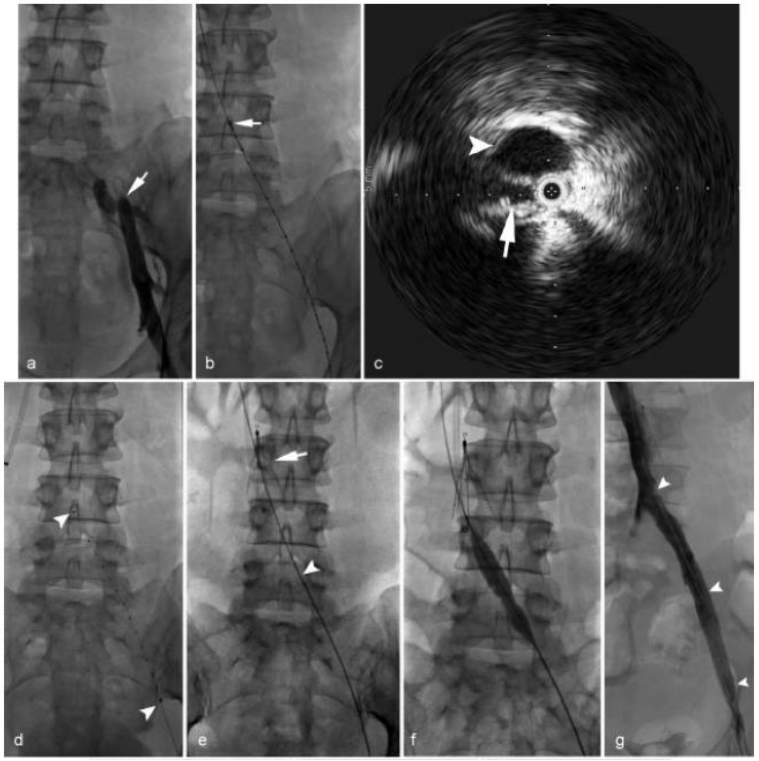

akuter Verschluss 34 Jahre weibl. (Flugreise)
Faktor V Leiden Mutation
«Taillenphänomen» Ballon

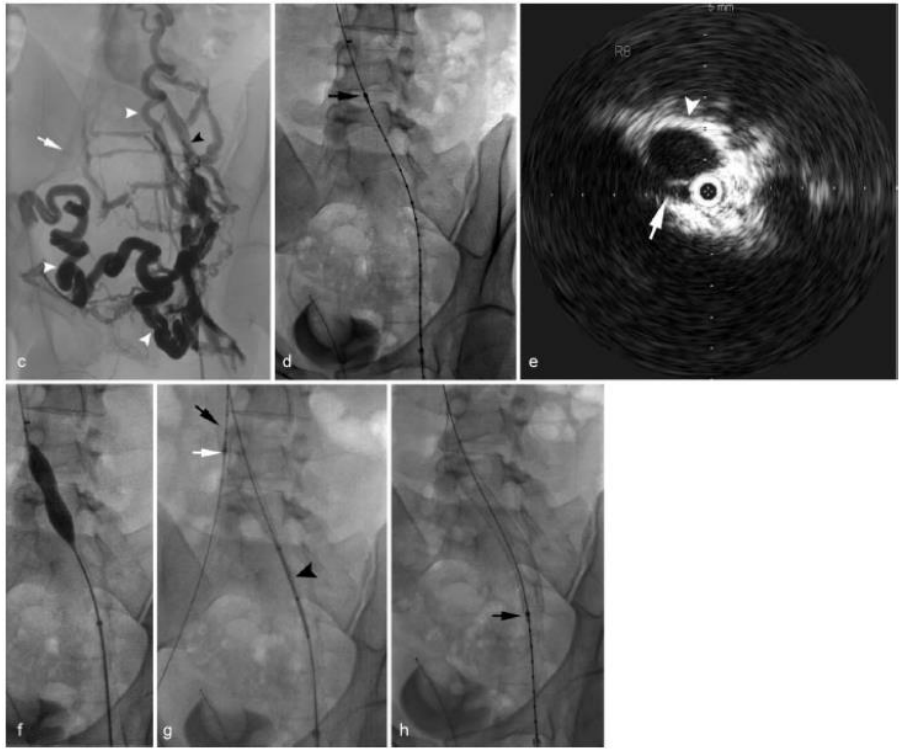

chronischer Verschluss (12 Jahre):
Schwellung/Schmerzen/Varikosis
«Taillenphänomen» Ballon

Majdalany et al 2017 Semin Int Rad

Patency nach Stenting

Stent	Studie	N=	FU Monate	primär %	sekundär
Venovo	Vernacular	219	12	88.9	-
VICI	Virtus	170	?	96.2	-
Neglen et al	retrospective	982	72	79 (57)	100 (86)
Ockert et al	retrospective	21	72	85.7	100

ca. 20% schlechtere Patency bei TVT/Verschluss vs. Stenosierung

Slippery when wet …

Slippery Stents: A Case Report and Review of the Literature Describing Patients with May-Thurner Syndrome That Experienced Stent Migration

Ramy Mando,[1] Priscilla Sigua-Arce,[1] Lisa Spencer,[2] and Alexandra Halalau[1,2]

[1]*Department of Internal Medicine, Beaumont Health System, Royal Oak, MI, USA*
[2]*Oakland University William Beaumont School of Medicine, Rochester Hills, MI, USA*

Correspondence should be addressed to Ramy Mando; ramy.mando@beaumont.org

Received 24 November 2018; Revised 17 February 2019; Accepted 19 February 2019; Published 5 March 2019

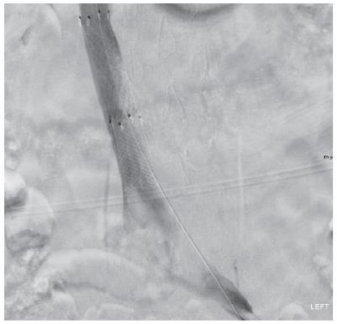

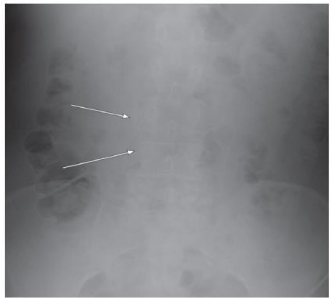

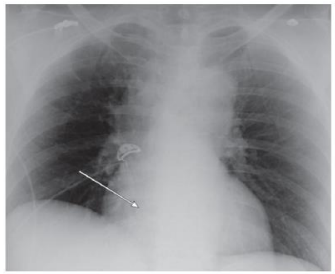

1. 14x60mm Luminexx Migration
2. 16x40 mm Wallstent Migration
3. 14x80 mm Luminexx

- Atemnot 1 Tag post-OP
- Bergung herzchirurgisch nach Stentnachweis rechter Vorhof

Literatur:

- Stentmigration in 6.25%
- Empfehlung primär endovaskuläre Bergung
- kardiochir. Behandlung mit relevante MM

Gerinnungmanagement post-Stenting ???

- ✓ 6-12 Monate OAK nach TVT
- ✓ dauerhafte OAK bei Rezidiv-TVT und/oder Thrombophilie
- Stenting bei Kompression ohne TVT: keine Vergleichsdaten ASS vs. OAK
- keine Daten direkte OAK (Xarelto) versus Marcumar

➢ keine Consensus bezüglich Plättchenhemmung und/oder OAK

➢ mögliche Vorteile der Kombination bei erhöhten Blutungsrisiko

Zusammenfassung

- ✓ May-Thurner = Normvariante (25% Normalbevölkerung); keine Pathologie
- ✓ MTS keine Indikation zur Behandlung asympt. Patienten
- ✓ keine Screening-Empfehlung in der Bevölkerung !!!

- ✓ symptomatsich/TVT in Kombination mit RF
- ✓ Quantifizierung ohne invasive Diagnostik schwierig/unmöglich
- ✓ Diagnostik Goldstandard: IVUS
- ✓ Stenting bei Nachweis Sporn/Stenose
- ✓ Antikoagulation Dauer und Art unklar

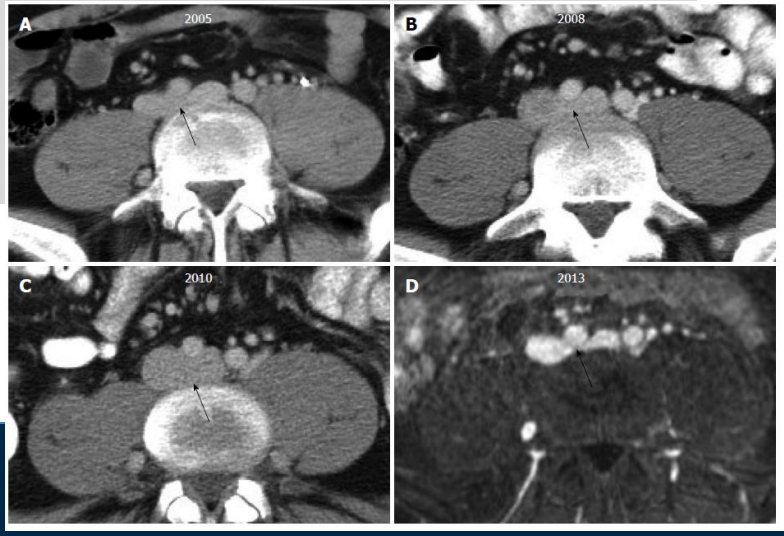

Zucker EJ Cardivasc Diagn Ther 2016

Vielen Dank !!!

stefan.ockert@luvas.ch